

# An Occult Laryngeal Foreign Body in A 2-Year-Old Child: A Case Report

Moujrid. Sara<sup>1\*</sup>, Sayarh.Meriem<sup>1</sup>, Bijou.Walid<sup>1</sup>, Oukessou.Youssef<sup>1</sup>, Rouadi Sami<sup>1</sup>, Abada Reda<sup>1</sup>, Roubal Mohamed<sup>1</sup>, Mahtar Mohamed<sup>1</sup>

<sup>1</sup>Department of Otorhinolaryngology, 20 Août Hospital, Casablanca, Morocco

**\*Corresponding Author:** Moujrid. Sara, Department of Otorhinolaryngology, 20 Août Hospital, Casablanca, Morocco

**Received:** 23 May 2024; **Accepted:** 04 June 2024; **Published:** 06 June 2024

**Citation:** Moujrid. Sara, et.al., (2024). An Occult Laryngeal Foreign Body in A 2-Year-Old Child: A Case Report. International Journal of Reproductive Research. 3(1). DOI: 10.58489/2836-2225/018

**Copyright:** © 2024 Moujrid. Sara, this is an open-access article distributed under the Creative Commons Attribution License, which permits unrestricted use, distribution, and reproduction in any medium, provided the original work is properly cited.

## Abstract

Lodgment of foreign bodies in the larynx is a relatively infrequent incident, given that aspirated foreign bodies generally traverse the respiratory tract and often get stuck in the lower airways. The diagnosis of a laryngeal foreign body poses significant challenges, particularly when the object in question is small, radiolucent, and induces partial airway obstruction. Foreign body aspiration (FBA) is commonly identified in pediatric cases, characterized by a sudden onset of symptoms such as cough, dyspnea, and wheezing. This manifestation becomes especially conspicuous when there are no underlying lung conditions like asthma or chronic pulmonary infections. The differential diagnosis hinges on a comprehensive scoring system that evaluates both clinical and radiological aspects. Presented here is a case involving a 4-year-old child with a laryngeal foreign body, initially misdiagnosed due to the patient's asymptomatic presentation. This case underscores the nuances of clinical manifestation, the investigative process, and subsequent management strategies.

**Keywords:** laryngeal foreign body, vocal cords, subglottic level

## Introduction

Foreign body aspiration refers to the introduction of solid objects into the airway, occurring at the level of the glottal opening, larynx, trachea, or bronchi [1]. This phenomenon poses a significant risk of morbidity and mortality, particularly in young children, ranking as the fourth leading cause of death in preschool-aged individuals [2]. The majority of aspirated foreign bodies traverse the larynx and become lodged in the tracheal or bronchial airways due to anatomical considerations [3].

The clinical presentation of a laryngeal foreign body is contingent upon factors such as its size, shape, nature, and the location of obstruction, or may manifest through complications, either immediate or delayed [4]. In this context, we present a noteworthy case involving a 4-year-old girl with a laryngeal foreign body, initially misdiagnosed. This instance emphasizes the rarity of such cases and underscores the importance of accurate diagnosis and prompt management.

## Case presentation

The onset of the illness traces back 20 days when the patient experienced an abrupt onset of respiratory

discomfort and a dry cough, leading the family to seek medical attention. Initially, the diagnosis was deemed an acute asthma attack, and the patient underwent background treatment for a duration of 15 days. However, given the persistent clinical context and lack of improvement with symptomatic treatment, a chest X-ray was ordered, revealing the presence of a foreign body in sagittal position (Figure 1).

As a complementary diagnostic measure, a cervical CT scan was conducted, confirming the existence of a laryngeal foreign body (Figure 2). Subsequently, the patient was referred to our department for further evaluation and management.

Upon clinical examination, the patient presented with a mildly hoarse voice, while surprisingly appearing comfortable. Chest examination did not reveal any specific findings, and systemic examination indicated a heart rate of 100/min, respiratory rate of 24/min, with 97% SpO<sub>2</sub> at room air. Flexible laryngoscopy under local anesthesia uncovered the presence of an impacted metallic foreign body in the subglottic region.

To address the situation, direct laryngoscopy under general anesthesia and spontaneous ventilation was performed, revealing a metallic foreign body in the

subglottic region. The foreign body, identified as a pendant necklace measuring 2cm in length and width, was successfully removed using alligator forceps without any incident (Figure 3). A subsequent examination showed no evidence of inflammation.

The patient was kept under observation status for 24 hours and was discharged home in good condition. A reevaluation conducted two weeks later indicated that the patient was asymptomatic, further highlighting the successful resolution of the case.

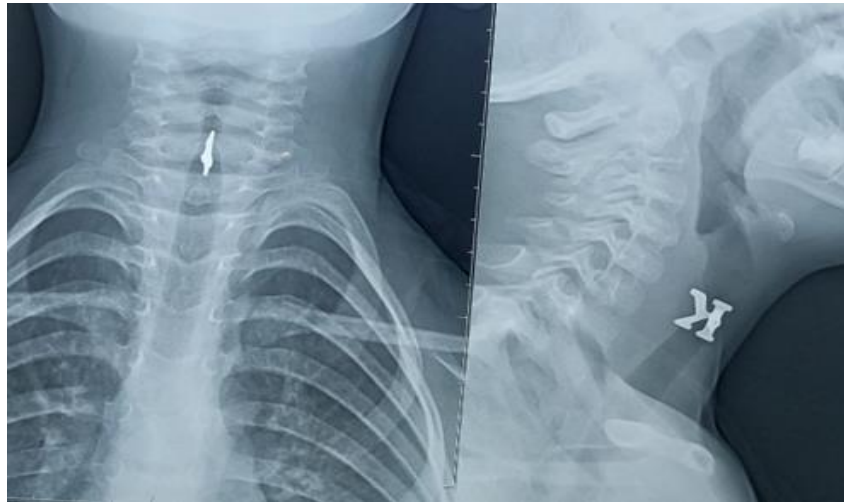


Fig 1: tomographic scan of neck showing the laryngeal airway foreign body

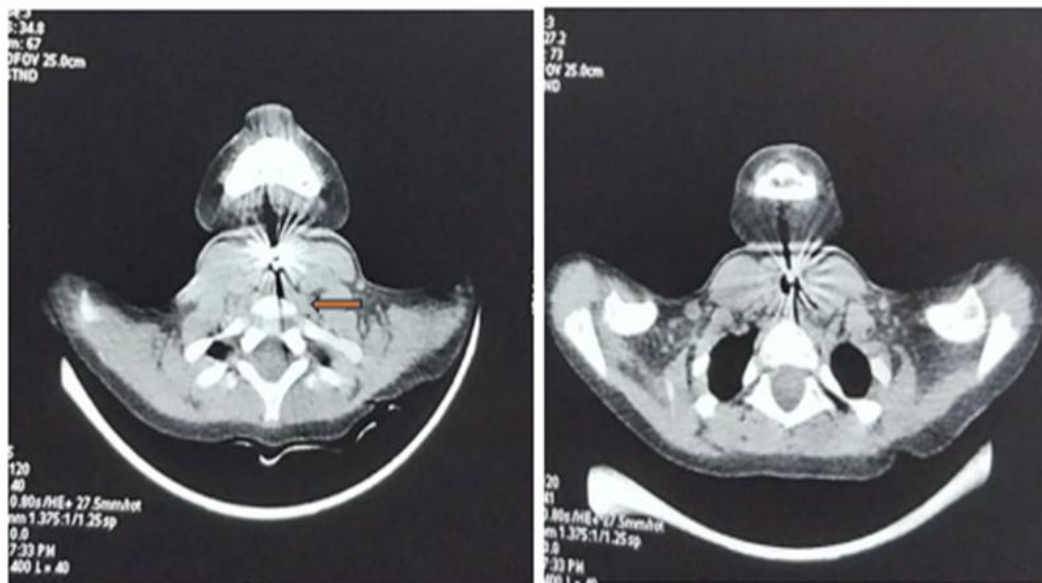


Fig 2: Neck CT scan axial section: The laryngeal airway foreign body (arrow).



**Fig 3:** photo of the foreign body after extraction

### Discussion

Foreign body aspiration, constituting a critical emergency, poses a substantial threat, particularly in the pediatric population, where it remains a leading cause of mortality. This life-threatening scenario can significantly compromise both oxygenation and ventilation, resulting in substantial morbidity or, in severe cases, even death. The diagnosis of foreign body aspiration presents challenges due to its varied presentation, ranging from overt choking incidents to subtle respiratory symptoms that may be easily overlooked [5].

Primarily affecting children between the ages of 1 and 3 years, a study conducted by Tang LF et al. [6] on 1027 children with foreign body aspiration reported a prevalence of 82.6% within the 1–3 years age group. Another comprehensive study by Ulas et al. [7] in 2022 underscored a significant number of cases in children under 3 years old, with sudden cough and wheezing being prominent symptoms.

The increased incidence in children is attributed to factors such as the introduction of adult food, oral tendencies, incomplete dentition, and immature swallowing coordination [5]. A retrospective review indicates a 2.5% mortality rate among pediatric patients, with age correlating to the anatomical location of the foreign body [8].

Upon analyzing available literature, meta-analyses affirm that the majority of foreign bodies are organic [9], with the bronchus being the most common location, accounting for less than 10% in the larynx [10]. Notably, Rothman et al. [11] found only 5 cases of laryngeal foreign bodies in a series of 225 patients.

Another study reveals that nuts emerged as a causative factor in 40% of cases across both high-income and low-middle-income nations. In the realm of inorganic foreign bodies, an analysis of literature from high-income countries indicated magnets as the causative agent in 34% of cases [12] [13].

Two types of foreign bodies may lodge in the larynx – large objects causing fatal airway obstruction and sharp, thin objects causing partial laryngeal obstruction [4]. Achieving an accurate diagnosis proves challenging, with patient history playing a pivotal role, given the potential absence of abnormalities in physical examinations [5].

Common symptoms encompass choking episodes, cyanosis, followed by coughing, stridor, and hoarseness. Sharp foreign bodies can manifest as mild dyspnea, hoarseness, and dysphagia, potentially being misdiagnosed as croup. A prospective study

[14] [15] cited a sensitivity of 91.1% and specificity of 45.2% for choking and acute cough. Wheeze on auscultation has been found to be a major physical finding and, in one study, was documented in 60% of cases. Haller et al.'s criteria [16] include sudden choking, apnea, decreased lung sounds as clinical parameters, and radiological parameters like lung atelectasis, air trapping, and mediastinal shift.

Unusual presentations, as observed in our case, may occur due to the thinness of the foreign body and its position, allowing free air passage. While conventional radiographs are commonly used for initial screening, their limitations, especially for radiolucent foreign bodies, pose a considerable risk of false negatives [17].

CT scans offer heightened sensitivity, but drawbacks include delayed treatment and patient irradiation. Hong et al. [18] demonstrated in their study that the overall sensitivity and specificity of CT scans were 100% and 66.7%, respectively. Thoracic computer tomography (CT) has been proposed as a diagnostic tool for radiolucent foreign bodies with minimal symptoms, as well as for those with recurrent, treatment-resistant respiratory infections [19] [20].

The removal of laryngeal foreign bodies under general anesthesia necessitates close collaboration between otolaryngologists and anesthesiologists to maintain the airway [21]. The gold standard for removal is rigid bronchoscopy in a spontaneously breathing patient, reducing the risk of ventilation issues during the procedure [22]. Complications, including recurrent pneumonia and bronchial stenosis, can arise from missed aspirations, emphasizing the importance of postoperative observation for children with delayed or technically challenging extractions that can lead to tracheostomy.

### Conclusion

Foreign body aspiration represents a potentially life-threatening yet entirely avoidable condition. The meticulous collection of accurate medical history stands as a pivotal element in informed clinical decision-making. As part of our proactive approach to health, we strongly advocate for the provision of anticipatory guidance to parents and caregivers. This involves educating and empowering them with the knowledge and awareness needed to prevent incidents of foreign body aspiration. By fostering a comprehensive understanding of potential risks and implementing preventive measures, we contribute significantly to diminishing the occurrence of this perilous condition. Establishing clear communication

channels between healthcare professionals, parents, and caregivers is also paramount, creating a supportive environment that actively works to prevent incidents of foreign body aspiration in young individuals.

### Declarations

#### Financial Disclosure

The authors declared that this study has received no financial support.

#### Authorship

All authors attest that they meet the current ICMJE criteria for Authorship.

#### Ethical approval

Written informed consent was obtained from the patient's parent for publication of this case report and accompanying images. A copy of the written consent is available for review by the Editor-in-Chief of this journal on request.

#### Financial Disclosure

This research did not receive any specific grant from funding agencies in the public, commercial, or not-for-profit sectors.

#### Declaration of Competing Interest

The authors declare that they have no known competing financial interests or personal relationships that could have appeared to influence the work reported in this paper.

### References

1. Marik, P. E. (2001). Aspiration pneumonitis and aspiration pneumonia. *New England Journal of Medicine*, 344(9), 665-671.
2. Pediatrics, A. A. P. (2010). Prevention of choking among children. *Pediatrics*, 125(3), 601-07.
3. Izadi, F., Hassannia, F., Maleki, M., Pousti, B., Koushki, E. S., & Mirhashemi, S. (2015). Occult laryngeal foreign body mimicking normal thyroid cartilage. *Trauma Monthly*, 20(3).
4. Brama, I., & Fearon, B. (1982). Laryngeal foreign bodies in children. *International Journal of Pediatric Otorhinolaryngology*, 4(3), 259-265.
5. S.R. Schoem, D.H. Darrow, K.W. Rosbe Aerodigestive tract foreign bodies American Academy of Pediatrics, Elk Grove Village, IL (2012) *Pediatric otolaryngology*
6. Dehghani, N., & Ludemann, P. (2008). Aspirated foreign bodies in children: BC Children's Hospital emergency room protocol. *BCMJ*, 50(5), 252-256.
7. Ulas, A. B., Aydin, Y., & Eroglu, A. (2022). Foreign body aspirations in children and adults. *The American Journal of Surgery*, 224(4), 1168-1173.
8. Johnson, K., Linnaus, M., & Notrica, D. (2017). Airway foreign bodies in pediatric patients: anatomic location of foreign body affects complications and outcomes. *Pediatric surgery international*, 33, 59-64.
9. Gvetadze, P., Chkhaidze, I., Baldas, S., Comoretto, R., Gregori, D., & Susy Safe Working Group. (2016). Injuries due to foreign body aspirations in Georgia: A prevention perspective. *International journal of pediatric otorhinolaryngology*, 83, 84-87.
10. Blazer, S., Naveh, Y., & Friedman, A. (1980). Foreign body in the airway: a review of 200 cases. *American Journal of Diseases of children*, 134(1), 68-71.
11. Rothmann, B. F., & Boeckman, C. R. (1980). Foreign bodies in the larynx and tracheobronchial tree in children: a review of 225 cases. *Annals of Otolaryngology, Rhinology & Laryngology*, 89(5), 434-436.
12. Chapin, M. M., Rochette, L. M., Annet, J. L., Haileyesus, T., Conner, K. A., & Smith, G. A. (2013). Nonfatal choking on food among children 14 years or younger in the United States, 2001–2009. *Pediatrics*, 132(2), 275-281.
13. Hanba, C., Cox, S., Bobian, M., Svider, P. F., Gonik, N. J., Shkoukani, M. A., & Sheyn, A. (2017). Consumer product ingestion and aspiration in children: A 15-year review. *The Laryngoscope*, 127(5), 1202-1207.
14. Foltran, F., Ballali, S., Rodriguez, H., van As, A. B., Passali, D., Gulati, A., & Gregori, D. (2013). Inhaled foreign bodies in children: a global perspective on their epidemiological, clinical, and preventive aspects. *Pediatric pulmonology*, 48(4), 344-351.
15. Lea, E., Nawaf, H., Yoav, T., Elvin, S., Ze'ev, Z., & Amir, K. (2005). Diagnostic evaluation of foreign body aspiration in children: a prospective study. *Journal of pediatric surgery*, 40(7), 1122-1127.
16. Haller, L., Barazzone-Argiroffo, C., Vidal, I., Corbelli, R., Anooshiravani-Dumont, M., & Mornand, A. (2018). Safely decreasing rigid bronchoscopies for foreign-body aspiration in children: an algorithm for the emergency department. *European Journal of Pediatric Surgery*, 28(03), 273-278.
17. Moskowitz, D., Gardiner, L. J., & Sasaki, C. T.



- (1982). Foreign-body aspiration: potential misdiagnosis. *Archives of Otolaryngology*, 108 (12), 806-807.
18. Hong, S. J., Goo, H. W., & Roh, J. L. (2008). Utility of spiral and cine CT scans in pediatric patients suspected of aspirating radiolucent foreign bodies. *Otolaryngology—Head and Neck Surgery*, 138(5), 576-580.
19. Rance, A., Mittaine, M., Michelet, M., Blondel, A. M., & Labouret, G. (2022). Delayed diagnosis of foreign body aspiration in children. *Archives de Pédiatrie*, 29(6), 424-428.
20. Buonsenso, D., Chiaretti, A., Curatola, A., Morello, R., Giacalone, M., & Parri, N. (2021). Pediatrician performed point-of-care ultrasound for the detection of ingested foreign bodies: case series and review of the literature. *Journal of Ultrasound*, 24, 107-114.
21. Sharma, H. S., & Sharma, S. (1999). Management of laryngeal foreign bodies in children. *Emergency Medicine Journal*, 16(2), 150-153.
22. Kent, S. E., & Watson, M. G. (1990). Laryngeal foreign bodies. *The Journal of Laryngology & Otology*, 104(2), 131-133.